Pain Medicine, 2025, **26**, 741–748
https://doi.org/10.1093/pm/pnaf070
Advance access publication 26 May 2025
Original Research Article

Radiological analysis of herniated disc size changes after percutaneous laser disc decompression

Roberto Gazzeri, MD*,[1], Felice Occhigrossi, MD[1], Marcelo Galarza, MD, PhD[2], Marco Mercieri, MD[3], Matteo Luigi Giuseppe Leoni, MD[3,4]

[1]Interventional and Surgical Pain Management Unit, San Giovanni Addolorata Hospital, 00184 Rome, Italy
[2]Regional Service of Neurosurgery, "Virgen de la Arrixaca" University Hospital, 30120 Murcia, Spain
[3]Department of Medical and Surgical Sciences and Translational Medicine, Sapienza University of Rome, 00100 Rome, Italy
[4]Unit of Interventional and Surgical Pain Management, Guglielmo da Saliceto Hospital, 0523 Piacenza, Italy

*Corresponding author: Interventional and Surgical Pain Management Unit, San Giovanni Addolorata Hospital, Via Amba Aradam 9, 00184 Rome, Italy. Email: robertogazzeri@gmail.com

Abstract

Objective: Symptomatic lumbar disc herniation is a major cause of low back pain and sciatica in adults, significantly affecting quality of life and creating economic burdens. Minimally invasive percutaneous intradiscal techniques, such as percutaneous laser disc decompression (PLDD), have been developed as alternatives to open surgery; however, their efficacy remains debated.

Design, Setting, and Subjects: This study evaluated the effectiveness of PLDD in patients with lumbar disc protrusions and contained herniations by assessing quantitative changes in herniated disc area on axial and sagittal MR images.

Methods: A total of 58 patients with lumbar radiculopathy due to disc herniation underwent MRI two months after PLDD to evaluate changes in disc area. Axial and sagittal MR images with the greatest protrusion and neural compromise were analyzed, and patient pain severity, clinical outcomes, and satisfaction were recorded.

Results: Results showed a statistically significant reduction in both axial and sagittal disc areas post-PLDD. The initial mean axial disc area of 0.51 cm^2 (0.44-0.58) decreased to 0.29 cm^2 (0.25-0.37), reflecting a median reduction of 35.9% ($P < 0.0001$). Similarly, the sagittal disc area decreased from a mean of 0.37 cm^2 (0.33-0.43) to 0.19 cm^2 (0.13-0.25), with a median reduction of 49.3% ($P < 0.0001$). All patients showed reductions in disc area, with a median reduction ratio of 52.7% (IQR: 45.2-56.2).

Conclusions: These findings suggest that PLDD is an effective option for reducing herniated disc size in carefully selected patients with contained disc herniations who have not responded to conservative treatment. Although not a substitute for open surgery, PLDD offers a statistically significant reduction in herniated disc size, making it a valuable therapeutic option for symptomatic contained lumbar disc herniation.

Keywords: percutaneous laser disc decompression (PLDD); lumbar disc herniation, minimally invasive spine surgery; herniated disc; MRI quantitative analysis in disc herniation.

Introduction

Symptomatic lumbar disc herniation represents one of the most common causes of functional limitation in the adult population, significantly impacting quality of life and posing a substantial economic burden due to disability and work absence.[1] The conservative management of contained lumbar disc herniation involves a multidisciplinary approach, including medical therapy, intraforaminal injections, and physiotherapy.[2] In cases where conservative and medical treatment fail, open surgical techniques may be considered for herniated disc treatment.[3] However, these surgical procedures are not without risk.[4] Over the years, several surgical approaches have been developed for the treatment of subacute and chronic back pain with or without radicular symptoms secondary to lumbar disc herniation. Despite ongoing debate about the efficacy of different treatment modalities, there has been growing interest in minimally invasive surgeries, such as percutaneous intradiscal techniques, for the treatment of herniated discs.[5–8] These minimally invasive surgical approaches often demonstrate lower complication rates with comparable outcomes, while also reducing hospitalization costs and morbidity.[9–11] Percutaneous Laser Disc Decompression (PLDD) has been developed as alternative treatment to open surgical techniques, especially for contained herniated disc.[12–16] PLDD employs laser energy to vaporize a small volume of the nucleus pulposus, aiming to reduce the herniated or protruding disc area. This reduction in disc size may lower intradiscal pressure, reducing the internal forces that cause irritation and compression of the adjacent lumbar nerve root.

Magnetic resonance imaging (MRI) is widely used in the diagnosis and treatment planning of patients with lumbar disc herniations. However, limited data exist on pre- and postoperative quantitative MRI measurements, such as herniated disc area and percentage of spinal canal compromise, to validate the effectiveness of surgical management.[17–20] The aim of this study was to evaluate the efficacy of PLDD in patients affected by lumbar disc protrusions and contained herniations by investigating the quantitative areal changes of herniated disc on axial and sagittal MR images following surgical treatment.

Methods

This study was a retrospective radiologic evaluation of patients with symptomatic lumbar disc contained herniation/

Received: 20 March 2025. **Revised:** 17 April 2025. **Accepted:** 9 May 2025
© The Author(s) 2025. Published by Oxford University Press on behalf of the American Academy of Pain Medicine. All rights reserved.
For commercial re-use, please contact reprints@oup.com for reprints and translation rights for reprints. All other permissions can be obtained through our RightsLink service via the Permissions link on the article page on our site—for further information please contact journals.permissions@oup.com.

Downloaded from https://academic.oup.com/painmedicine/article/26/11/741/8149198 by Georgia Institute of Technology user on 14 March 2026

protrusion who underwent PLDD. All procedures adhered to the ethical standards of the institutional research committee and the 1964 Helsinki declaration, and the study was approved by the local ethic committee (570/2022/OSS/ASLPC). Experienced neurosurgeons and pain physicians performed all procedures. Hospital records were reviewed, and patients' demographic data, including surgical indication, treatment levels, operative details, and complications, were collected using standardized data collection forms. A total of 165 patients with low back pain and sciatica, confirmed by MRI to have single-level lumbar intervertebral disc herniation, were identified through diagnostic codes and chart review. Of these, 87 received PLDD, but 29 patients were lost to follow-up or did not undergo postoperative lumbar spinal MRI. In our protocol, a postoperative lumbar MRI was performed two months after the PLDD procedure to assess the anatomical outcome. Thus, 58 patients who had sufficient clinical data and 2-month postoperative MR images, were included in the study. Baseline data collected included patient age, sex, body mass index (BMI), smoking status, analgesic use, and duration of symptoms.

All patients reported unilateral or bilateral leg pain, had a positive nerve root tension sign, or experienced severe back pain worsened by spinal flexion. MRI findings confirmed single contained symptomatic focal disc protrusion between L2 and S1, which did not compromise more than one-third of the antero-posterior diameter of the spinal canal. Patients exhibited minimal myotonal deficit (motor strength $\geq$ 4/5), with symptoms consistent with the level of disc herniation. Each patient had received one or more treatments for over 4 months, including analgesics, nonsteroidal anti-inflammatory drugs, oral steroids, physical therapy, spinal injections or chiropractic treatment. Exclusion criteria were lack of supervised conservative treatment, MRI evidence of extruded or sequestered disc herniation, disc height reduction > 50%, history of open discectomy at the affected level, spinal fracture, tumor or infection, focal protrusion exceeding one third of the spinal canal, hyperostosis causing foraminal stenosis at the symptomatic level; myotonal deficit with motor strength less than 4/5, significant spinal stenosis or prior spinal surgery. Preoperative MRI scans were available for evaluation for all included patients.

Surgical technique

PLDD was performed in the operating room with the patient in the prone position, under mild sedation. Patients received antibiotic prophylaxis with 2 g of cefazolin, administered intravenously within 30 min surgery. The soft tissues were infiltrated with local anesthetic for 8-10 cm lateral to the midline of the spine. Under fluoroscopic guidance in oblique projection, a 18- or 20-gauge spinal needle was inserted through the annulus fibrosus into the nucleus pulposus of the affected disc. Once the needle was correctly positioned within the disc space, the position of the tip of the needle within the center of the nucleus pulposus was confirmed by antero-posterior and lateral X-ray views. In all cases, intraoperative discography was performed by injecting contrast medium in the nucleus pulposus, to assess disc morphology and annulus fibrosus integrity. A 400-micron optical fiber, protruding 1.00 mm beyond the edge of the needle and secured with a set-screw plastic disc to prevent migration, was then inserted. The optical fiber was connected to a 1470 nm laser diode (NeoV, Neolaser, Caesarea, Israel), calibrated to emit 7 watts at 1.0 s burst (7 joules). Laser energy was delivered at 7-joule intervals with 1 to 3 s pauses until a total of 800 joules was reached. At the end of the procedure, 1 mL of broad-spectrum antibiotic (Gentamycin) was injected into the disc. No sutures nor Steri-Strips were applied. Patients were advised to remain in bed during the procedure day, with regular indoor and outdoor activities, including back muscle exercises, allowed starting from the second postoperative day.

Clinical outcome measures

The patients' pain severity was assessed by the Visual Analogue Scale (VAS) (0 = no pain; 1-3 = mild pain; 4-6 = moderate pain; 7-10 = severe pain), while neuropathic pain was screened using the DN4 score (Douleur Neuropathique en 4 Questions). Clinical status was assessed when patients returned for follow-up examination at 1 and 6 months along with patient satisfaction. In case of complications, the specific nature was recorded.

Radiographic analysis

Baseline and 2 months post-surgery follow-up MRIs were available and archived for 58 patients. The images were collected electronically and stored directly as DICOM files. All images were de-identified to ensure patient confidentiality. High-resolution scans of both T1- and T2-weighted series in sagittal and axial planes were available for each case. The herniated disc area was measured using Radiant DICOM Viewer software (Medixant, RadiAnt DICOM Viewer Software, Version 2024.1, https://www.radiantviewer.com) which allows for precise area and distance measurements between two user-defined points, and is particularly useful for measuring irregularly shaped object.

For each patient, the axial and sagittal T2-weighted images showing the greatest disc nucleus herniation/protrusion and maximal amount of canal or neural foramen compromise were selected for measurement. The boundaries of the herniated disc were segmented using the viewer tool to measure the cross-sectional area and antero-posterior length of the herniation. Lumbar disc herniation was assessed by marking the area of the herniated disc between the lateral margins of the vertebral pedicles. Within the axial and sagittal views of MRI images, the following measurements were made for disc herniation/protrusion: The total herniated disc area and the antero-posterior length of the herniated disc. The area was measured using as many points as the user felt necessary in order to trace a proper segmentation of the disc herniation. An example of lumbar disc herniation measurements before and after PLDD is shown in Figure 1. To calculate the reduction ratio of the herniated disc, the following formula was used: [(D-d)/D] x 100, where D is the distance between the base and the tip of the herniation before PLDD, and d is the same distance after the surgical procedure (Figure 2).[21] Quantitative measurements were performed by an independent reviewer, who was blinded to patient's identity.

Statistical analysis

A descriptive statistical analysis was conducted. Continuous variables are presented as median with interquartile range (IQR), while categorical variables are shown as counts and percentages. Normality of the data was evaluated using the Shapiro-Wilk test. Differences between pre- and post-operative continuous variables were assessed using the Wilcoxon rank-sum test. The changes of NRS at 1 month and

Downloaded from https://academic.oup.com/painmedicine/article/26/11/741/8149198 by Georgia Institute of Technology user on 14 March 2026

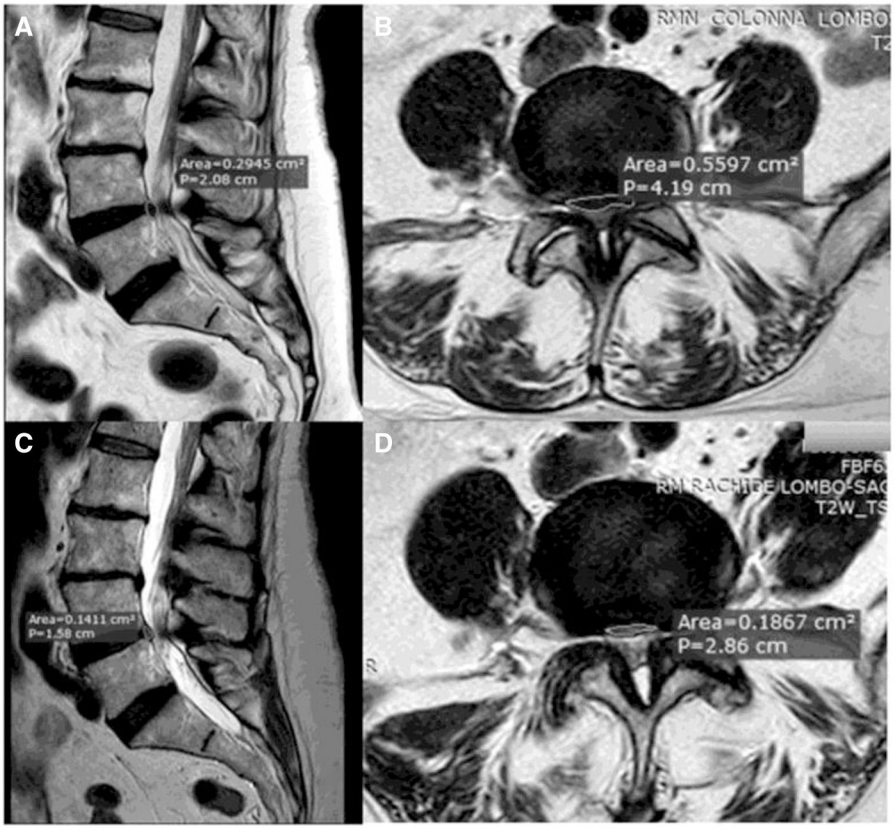

Figure 1. Axial and sagittal T2-weighted MR images depicting the points of greatest canal compromise. The images illustrate an example of herniated disc measurements taken before (A, B) and after (C, D) percutaneous laser disc decompression (PLDD).

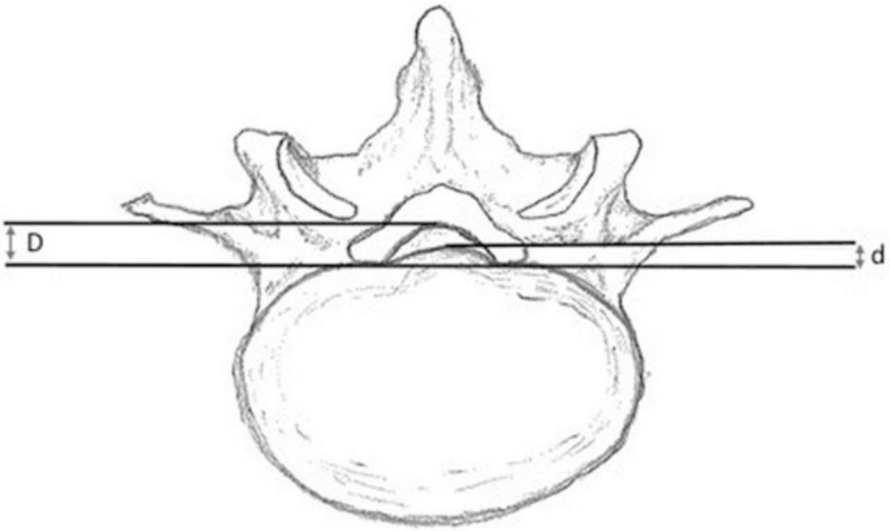

Figure 2. The figure demonstrates the assessment of the herniated disc reduction ratio. As detailed in the text, the reduction ratio was calculated using the formula: [(D-d)/D] x 100. Here, D represents the distance from the base to the tip of the herniation before the PLDD procedure, while d indicates the corresponding distance measured after the surgical intervention.

6 months were evaluated via a one-way analysis of variance. Changes in NRS scores at 1 month and 6 months post-treatment were assessed using a one-way analysis of variance (ANOVA) followed by Dunn's multiple comparisons test. To explore associations between axial and sagittal reduction areas, reduction ratio, and potential predictive variables (age, gender, BMI, PLDD surgical level, and pain duration), multiple linear regression models were employed. Coefficients are provided with 95% confidence intervals. Variance inflation factors (VIFs) were calculated to assess multicollinearity, which was ruled out as all variables showed VIFs below 0.7.[22] Statistical significance was set at a two tailed P value < 0.05. *R* v4.2.2 (*R* Foundation for Statistical Computing, Vienna, Austria, www.rproject.org) was used for the analyses.

Downloaded from https://academic.oup.com/painmedicine/article/26/11/741/8149198 by Georgia Institute of Technology user on 14 March 2026

Results

In the present study, we included all patients who underwent surgery between January 2022 and April 2024 and completed a 2-month postoperative radiologic follow-up with MRI imaging. This yielded 58 consecutive patients (31 males, 27 females) with a mean follow-up of 13.8 months. The median age of the included patients was 63.5 years (57-71), with a median BMI of 22 Kg/m^2 (21-23). The most treated herniated disc level was L4-L5 (59%), followed by L5-S1 (31%). Preoperative data are summarized in Table 1. The mean surgical procedure time (from the induction of local anesthesia to the removal of the spinal needle) was 14.6 min. No patient experienced pain during the laser decompression, while minor pain was evoked during discography due to disc pressurization with the contrast. No major or minor perioperative complications were reported, and no side effects were observed during the follow-up period. Preoperative NRS decreased from 8.5 (7-9) to 2 (2-3) at 1 month and to 2 (1-3) at 6 months follow-up, respectively, $P < 0.0001$. No significant change in NRS was observed between the 3- and 6-month follow-ups, $P = 0.9$. A significant linear relationship was observed between preoperative NRS and both preoperative axial disc area ($R^2 = 0.08$, $P = 0.03$) and preoperative sagittal disc area ($R^2 = 0.14$, $P = 0.004$). The DN4 score significantly decreased from preoperative to postoperative follow-up (preoperative DN4: 5 (4-6), postoperative DN4: 1 (0-2), $P < 0.0001$). Preoperatively, 32 (55.1%) patients used analgesics regularly, while 27 (46.5%) used pain medications occasionally. At the final follow-up, no analgesic use was reported in half of the cases (50%), and regular analgesic use was reported in 10.3% of cases. Only 2 patients reported persistent back pain during the first week after surgery, which resolved completely by the first follow-up visit. Successful clinical outcomes, defined as a NRS reduction of at least 50% at the 6-month follow-up compared to baseline, were achieved in 57 out of 58 patients (98%). Only one patient with an L4-L5 disc herniation achieved a 43% NRS reduction at the 6-month follow-up. At 6 months following PLDD, patient-reported satisfaction levels were as follows: 46 patients (79%) reported being satisfied, 9 patients (16%) were undecided, and 3 patients (5%) were dissatisfied.

The initial mean axial and sagittal disc areas of the herniated disc on MR images were 0.51 cm^2 (0.44-0.58) and 0.37 cm^2 (0.33-0.43), respectively. At 2 months following PLDD, a significant reduction in the axial herniated disc area was observed, with a preoperative axial disc area of 0.51 cm^2 (0.44-0.58) decreasing to a postoperative area of 0.29 cm^2 (0.25-0.37), $P < 0.0001$, reflecting a median reduction of 35.9% (−47.1% to −31.6%). Similar findings were noted for the sagittal area, where the preoperative sagittal herniated disc area of 0.37 cm^2 (0.33-0.43) decreased to 0.19 cm^2 (0.13-0.25) postoperatively, $P < 0.0001$, resulting in a median reduction of 49.3% (−63.9% to −39%), (Figure 3). A reduction in herniated disc area was observed in all patients included. A median reduction ratio of 52.7% (IQR: 45.2-56.2) was observed.

In analyzing the factors associated with the axial and sagittal reduction of herniated disc areas, as well as the reduction ratio following treatment, several independent variables were assessed. For the axial reduction area after PLDD, none of the evaluated variables such as age, gender, BMI, surgical level, and pain duration showed statistically significant associations. In contrast, for the sagittal reduction area, pain duration emerged as the only predictor showing a significant association, with a coefficient of −1.3 (95% CI: −2.7 to −0.003, $P = 0.04$), suggesting that longer pain duration is linked to a greater reduction in sagittal herniated disc area. Similarly, for the reduction ratio, pain duration was significantly associated with a positive change, with a coefficient of 0.78 (95% CI: 0.22 to 1.35, $P = 0.008$), implying that a longer pain duration correlates with an increased reduction ratio. Other variables, such as age, gender, BMI, and surgical level of PLDD, did not show significant associations with the reduction ratio (Table 2).

A significant negative association was observed between the axial reduction area and the median NRS percentage reduction at the 6-month follow-up ($r = -0.29$, $P = 0.03$), suggesting that a greater reduction in axial herniated disc area is associated with greater improvements in pain scores (Figure 4A). Similarly, a negative association was found between the sagittal reduction area and the median NRS percentage reduction at the 6-month follow-up ($r = -0.37$, $P = 0.004$), as shown in Figure 4B. In contrast, a significant positive association was identified between the reduction ratio and NRS percentage reduction at the 6-month follow-up ($r = 0.27$, $P = 0.04$), indicating that a higher reduction ratio correlates with further decreases in pain scores (Figure 4C).

Table 1. Characteristics of the treated patients.

Variable	Total patients included ($n = 58$) n. (%)
Age, years	63.5 (57-71)
Gender	
Male	31 (53.5%)
Female	27 (46.5%)
BMI	22 (21-23)
Pain duration, months	6 (5-9)
Level of disc herniation	
L2-L3	2
L3-L4	2
L4-L5	13
L5-S1	4
Double disc herniation level	7 (25%)
L3-L4 and L4-L5	6
L4-L5 and L5-S1	1

Discussion

In the current study, we present an objective quantitative assessment and comparison of disc area changes following PLDD in humans. Our data revealed a median reduction of 35.9% in the axial disc area and 49.3% in the sagittal disc area at 2 months post-PLDD. Along with the morphological changes in disc herniation observed after PLDD, a reduction of at least 50% in NRS scores at the 6-month follow-up, compared to baseline, was achieved in 57 out of 58 patients (98%). When conservative treatments fail to achieve adequate pain relief in patients with herniated disc, invasive treatments may be considered.[23–25] Patients with small, contained disc herniations or protrusions unresponsive to non-invasive treatments are often potential candidates for surgical interventions, such as microdiscectomy. However, before opting for invasive surgery, several minimally invasive procedures have emerged as viable alternatives to conventional open surgery. These include intradiscal electrothermal

Downloaded from https://academic.oup.com/painmedicine/article/26/11/741/8149198 by Georgia Institute of Technology user on 14 March 2026

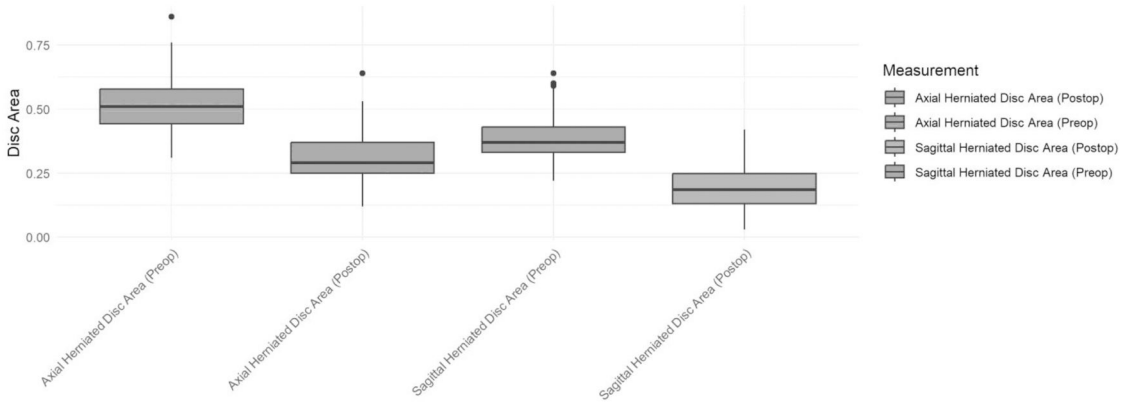

Figure 3. Preoperative and postoperative axial and sagittal herniated disc areas. The box plots illustrate the significant reduction in axial and sagittal herniated disc areas on MRI, comparing measurements taken before (Preop), and after (Postop) percutaneous laser disc decompression (PLDD).

Table 2. Multiple linear regression analyses assessing the relationship between potential predictive variables and the axial and sagittal reduction areas, as well as the reduction ratio with possible predicting variables.[a]

	Dependent variable: axial reduction area		
Independent variables	**Coefficient**	**95% CI**	***P* value**
Age	−0.09	−0.45 to 0.27	0.62
Gender			
Female	Reference category		
Male	1.53	−6.95 to 10.02	0.72
BMI	−0.12	−2.92 to 2.68	0.93
Herniated disc level			
L2-L3	Reference category		
L3-L4	14.68	−6.11 to 35.47	0.16
L4-L5	7.78	−11.60 to 27.15	0.42
L5-S1	9.49	−10.40 to 29.40	0.34
Pain duration	−0.64	−1.70 to 0.42	0.23
Dependent variable: sagittal reduction area			
Age	0.08	−0.38 to 0.53	0.73
Gender			
Female	Reference category		
Male	2.23	−8.5 to 12.9	0.68
BMI	1.73	−7.54 to 10.99	0.70
Herniated disc level			
L2-L3	Reference category		
L3-L4	26.2	−0.16 to 52.5	0.051
L4-L5	11.4	−13.2 to 35.9	0.36
L5-S1	12.4	−12.8 to 37.6	0.33
Pain duration	−1.3	−2.7 to −0.003	**0.04**
Dependent variable: reduction ratio			
Age	−0.01	−0.20 to 0.18	0.92
Gender			
Female	Reference category		
Male	−3.34	−7.89 to 1.21	0.15
BMI	0.68	−0.82 to 2.18	0.37
Herniated disc level			
L2-L3	Reference category		
L3-L4	−9.95	−21.11 to 1.21	0.08
L4-L5	−7.12	−17.5 to 3.28	0.18
L5-S1	−6.93	−17.6 to 3.75	0.20
Pain duration	0.78	0.22 to 1.35	**0.008**

[a] The coefficients for each predictor are reported along with the 95% confidence interval.
Bold values indicate statistically significant results ($P < 0.05$).

therapy, nucleoplasty, and laser spine surgery.[9–11,15,26,27] Among these procedures, PLDD offers a promising therapeutic option with a mechanism centered on intradiscal decompression.[12,14,16]

PLDD may be considered for patients experiencing severe symptoms, recurrent episodes, and lack of response to conservative treatments. It has demonstrated both safety and success, with encouraging outcomes reported in multiple clinical trials.[28] The underlying principle of PLDD is based on closed hydraulic system theory: PLDD indirectly decompress the affected nerve root by using laser energy to vaporize a small volume of the nucleus pulposus, thereby reducing intervertebral disc pressure.[16,29] Even a minimal reduction in nucleus pulposus volume results in a significant decrease in intradiscal pressure, effectively alleviating nerve root compression.

There is limited information in the literature comparing MRI assessments of lumbar disc herniation area and canal compromise before and after surgery, with size measurements obtained using various methods.[19,30,31] Although numerous studies discuss morphological changes in disc herniations following minimally invasive treatments, quantitative areal data following PLDD have not been widely reported.[19,31] To our knowledge, this is the first study performed in humans to provide a quantitative assessment of disc area change after PLDD. This study investigated the likelihood of radiological success following PLDD. Typically, postoperative MRI is not routinely performed after surgical decompression of disc herniation unless persistent or recurrent symptoms occur.[32] However, in our study, follow-up MRI scans were conducted two months postoperatively to assess the reduction in lumbar disc herniation, regardless of clinical symptoms. Our results demonstrated a statistically significant reduction in the size of the herniated disc area, with a median reduction of 35.9% in the axial plane and 49.3% in the sagittal plane, yielding an overall median reduction ratio of 52.7%. Furthermore, the axial and sagittal herniation areas provided sufficient detail to observe anatomical disc changes following PLDD.

In our series, a statistically significant correlation was observed between the preoperative NRS scores and the herniated disc area measured on baseline MRI. Similarly, Pneumaticos et al. reported that a sagittal diameter of 6.8 mm in herniated discs was associated with the presence of low back pain, with a sensitivity and specificity of 95%.[33]

The integrity of the annulus fibrosus is a crucial factor for achieving favorable outcomes after PLDD. Consequently, the optimal indications for PLDD are disc protrusions and contained herniations. In our cases we performed discography with contrast medium injection into the nucleus to confirm annulus fibrosus integrity. Open surgical procedures for

Downloaded from https://academic.oup.com/painmedicine/article/26/11/741/8149198 by Georgia Institute of Technology user on 14 March 2026

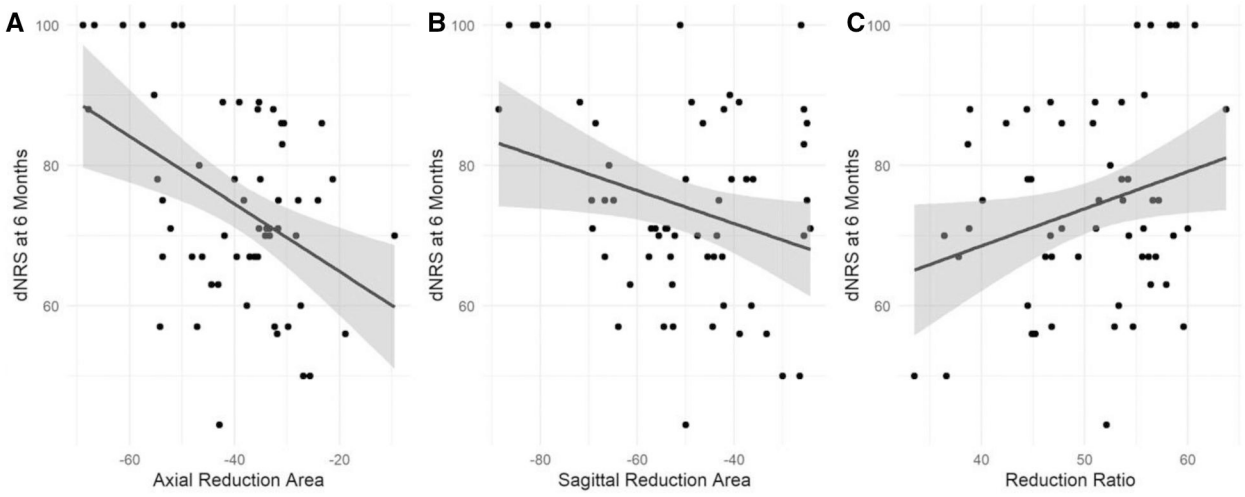

Figure 4. Linear regressions of median NRS percentage reduction at the 6-month follow-up (dNRS) with axial reduction area (A), sagittal reduction area (B), and reduction radio (C).

lumbar disc herniation are not without adverse events, as they can lead to epidural fibrosis with nerve adhesions, spinal instability, hemorrhages, and other complications.[34–37] In our series, no major or minor complications occurred. Modic changes (Type 1) were observed on MRI in two cases of postoperative persistent back pain lasting one week. The extent to which areal changes in herniated discs are attributable to PLDD versus natural physiologic shrinkage remains uncertain. While spontaneous regression of disc herniation is a documented phenomenon, it is more commonly observed in cases of sequestered herniated discs.[38,39] Transligamentous extension promotes disc resorption, with larger discs generally more prone to size reduction than smaller ones.[40,41] Although disc herniations can sometimes spontaneously regress and symptoms may improve with conservative treatment, the indication for PLDD in our patients was based on persistent, drug-resistant pain following a minimum of four months of conservative therapy. In our series, all patients had contained or protruding disc herniations, which are less likely to undergo spontaneous resorption and therefore more suited to intervention with PLDD.A postoperative MRI was conducted two months following surgery to assess the short-term effects of PLDD on the disc. This timing was chosen to minimize the bias of any potential natural regression of the herniated disc, isolating the specific impact of PLDD. Interestingly, our analysis revealed a statistically significant association between pain duration and reduction in herniated disc area among the included patients. This relationship may be attributed to physiological mechanisms of disc shrinkage, which may have been initiated prior to PLDD and further amplified by the procedure. One possible explanation for this finding is that prolonged pain duration could reflect biochemical changes within the disc, leading to structural adjustments that predispose it to shrinkage when exposed to PLDD. Another factor could be an increased susceptibility of the nucleus pulposus to laser-induced vaporization in discs with a prolonged history of degeneration, resulting in more pronounced decompression and volume reduction. Further investigation into these mechanisms would help clarify how pain duration contributes to PLDD outcomes. In contrast, no significant association was identified between patient age, gender, BMI, or the treated disc level and changes in the size of the herniated disc.

Interestingly, a significant association was identified between the reduction in herniated disc areas (both axial and sagittal) and the reduction ratio with the median NRS percentage improvement at the 6-month follow-up. These findings underscore the complex mechanisms underlying radicular pain in disc herniation, suggesting that pain is not solely driven by local inflammatory reactions but is also significantly influenced by mechanical compression exerted on the nerve root.[1,42,43] This dual mechanism—where both inflammation and physical pressure contribute to symptoms—emphasizes the importance of reducing disc volume to alleviate pain effectively. This insight provides further rationale for treatments like PLDD, which effectively decompresses the herniated disc volume.

This study has several limitations. First, the small sample size limits generalizability, though a clear reduction in herniated disc dimensions was observed across all included patients. Second, the absence of a conservative control group presents a significant design limitation. Additionally, the retrospective nature of the study introduces potential selection bias, although consecutive patient inclusion was employed to mitigate this effect. Herniated disc measurements were performed by a single experienced neurosurgeon specializing in disc surgery and imaging segmentation, which, while ensuring consistency, precludes assessment of interobserver reliability. Another notable limitation is the timing of the MRI assessments, as we were unable to evaluate whether long-term follow-up MRIs might reveal further reduction in herniated disc dimensions. In our series, we did not add disc supplement after the disc decompression. Direct supplementation of degenerated disc tissue may represent further opportunity after PLDD and may contribute to disc restoration. Future studies providing a comparison between PLDD alone and PLDD with disc supplement are recommended.

Conclusions

PLDD is a minimally invasive surgical approach that effectively treats patients with symptomatic contained disc herniation who have not responded to conservative therapies and

Downloaded from https://academic.oup.com/painmedicine/article/26/11/741/8149198 by Georgia Institute of Technology user on 14 March 2026

are either unsuitable candidates for, or wish to avoid, open discectomy. This study's findings demonstrate a statistically significant reduction in herniated disc size following PLDD. With careful patient selection and adherence to proper indications, PLDD can be a valuable option for managing contained disc herniations. However, it should not be considered a substitute for open surgery.

Author contributions

Roberto Gazzeri, Marcelo Galarza, Matteo Luigi Giuseppe Leoni: Designing the protocol, writing the protocol and manuscript. Roberto Gazzeri, Marcelo Galarza, Matteo Luigi Giuseppe Leoni, Marco Mercieri, Felice Occhigrossi: Extracting and analyzing data, interpreting results.

Funding

None declared.

Conflicts of interest: None declared.

Ethical approval

All procedures performed in studies involving human participants were in accordance with the ethical standards of the institutional and/or national research committee and with the 1964 Helsinki Declaration and its later amendments or comparable ethical standards. The study was approved by the local ethic committee (approval number 570/2022/OSS/ASLPC).

References

1. Urits I, Burshtein A, Sharma M, et al. Low back pain, a comprehensive review: pathophysiology, diagnosis, and treatment. *Curr Pain Headache Rep*. 2019;23(3):23.
2. Oliveira CB, Maher CG, Pinto RZ, et al. Clinical practice guidelines for the management of non-specific low back pain in primary care: an updated overview. *Eur Spine J*. 2018;27(11):2791-2803.
3. Dewing CB, Provencher MT, Riffenburgh RH, Kerr S, Manos RE. The outcomes of lumbar microdiscectomy in a young, active population: correlation by herniation type and level. *Spine*. 2008;33(1):33-38.
4. Imagama S, Ishiguro N, Kawakami N, et al. Perioperative complications and adverse events after lumbar spinal surgery: evaluation of 1012 operations at a single center. *J Orthop Sci*. 2011;16(5):510-515.
5. Choy DS, Ascher PW, Ranu HS, et al. Percutaneous laser disc decompression A new therapeutic modality. *Spine*. 1992;17(8):949-956.
6. Gazzeri R, Tribuzi S, Galarza M, Leoni MLG, Occhigrossi F. Ultrasound-guided Percutaneous Laser Disc Decompression (PLDD) with fluoroscopic validation for the treatment of cervical disc herniation: technical note. *Pain Med*. 2023;24(6):625-632. https://doi.org/10.1093/pm/pnac188. PMID: 36469340.
7. Lee SH, Kang HS. Percutaneous endoscopic laser annuloplasty for discogenic low back pain. *World Neurosurg*. 2010;73(3):198-206; discussion e33.
8. Simon C, Le Corroller T, Pauly V, Creze M, Champsaur P, Guenoun D. Intradiscal oxygen-ozone therapy for the treatment of symptomatic lumbar disc herniation: a preliminary study. *J Neuroradiol*. 2022;49(2):180-186.
9. Brouwer PA, Peul WC, Brand R, et al. Effectiveness of percutaneous laser disc decompression versus conventional open discectomy in the treatment of lumbar disc herniation; design of a prospective randomized controlled trial. *BMC Musculoskelet Disord*. 2009;10:49.
10. Gogos C, Filippiadis DK, Velonakis G, Kelekis N, Papagelopoulos P, Kelekis A. Intradiscal gelified ethanol nucleolysis versus endoscopic surgery for lumbar disc herniation radiculopathy. *Diagnostics (Basel)*. 2023;13(13):2164.
11. Kelekis A, Bonaldi G, Cianfoni A, et al. Intradiscal oxygen-ozone chemonucleolysis versus microdiscectomy for lumbar disc herniation radiculopathy: a non-inferiority randomized control trial. *Spine J*. 2022;22(6):895-909.
12. Gazzeri R, Tribuzi S, Galarza M, Occhigrossi F. Percutaneous laser disc decompression (PLDD) for the treatment of contained lumbar disc herniation. *Surg Technol Int*. 2022;41:1;403-407.
13. Gazzeri R, Leoni MLG, Occhigrossi F. Efficacy of Percutaneous Laser Disc Decompression (PLDD) combined with an oral food supplement for lumbar disc herniation. *J Clin Med*. 2024;13(17):5049.
14. McMillan MR, Patterson PA, Parker V. Percutaneous laser disc decompression for the treatment of discogenic lumbar pain and sciatica: a preliminary report with 3-month follow-up in a general pain clinic population. *Photomed Laser Surg*. 2004;22(5):434-438.
15. Plapler H, Mancini MW, Sella VR, Bomfim FR. Evaluation of different laser wavelengths on ablation lesion and residual thermal injury in intervertebral discs of the lumbar spine. *Lasers Med Sci*. 2016;31(3):421-428.
16. Schenk B, Brouwer PA, Peul WC, van Buchem MA. Percutaneous laser disk decompression: a review of the literature. *AJNR Am J Neuroradiol*. 2006;27(1):232-235.
17. Carragee EJ, Kim DH. A prospective analysis of magnetic resonance imaging findings in patients with sciatica and lumbar disc herniation. Correlation of outcomes with disc fragment and canal morphology. *Spine (Phila Pa 1976)*. 1997;22(14):1650-1660.
18. Gupta A, Upadhyaya S, Yeung CM, et al. Does size matter? An analysis of the effect of lumbar disc herniation size on the success of nonoperative treatment. *Global Spine J*. 2020;10(7):881-887.
19. Heo JH, Kim CH, Chung CK, et al. Quantity of disc removal and radiological outcomes of percutaneous endoscopic lumbar discectomy. *Pain Phys*. 2017;20(5):E737-E746.
20. Mysliwiec LW, Cholewicki J, Winkelpleck MD, Eis GP. MSU classification for herniated lumbar discs on MRI: toward developing objective criteria for surgical selection. *Eur Spine J*. 2010;19(7):1087-1093.
21. Chung TS, Yang HE, Ahn SJ, Park JH. Herniated lumbar disks: real-time MR imaging evaluation during continuous traction. *Radiology*. 2015;275(3):755-762.
22. Kim JH. Multicollinearity and misleading statistical results. *Korean J Anesthesiol*. 2019;72(6):558-569.
23. Choy DS. Percutaneous laser disc decompression (PLDD): a first line treatment for herniated discs. *J Clin Laser Med Surg*. 2001;19(1):1-2.
24. Hammed A, Al-Qiami A, Alsalhi H, et al. Surgical vs. conservative management of chronic sciatica (>3 months) due to lumbar disc herniation: systematic review and meta-analysis. *Cureus*. 2024;16(5):e59617.
25. Rasouli MR, Rahimi-Movaghar V, Shokraneh F, Moradi-Lakeh M, Chou R. Minimally invasive discectomy versus microdiscectomy/open discectomy for symptomatic lumbar disc herniation. *Cochrane Database Syst Rev*. 2014;2014(9):CD010328.
26. Eichen PM, Achilles N, Konig V, et al. Nucleoplasty, a minimally invasive procedure for disc decompression: a systematic review and meta-analysis of published clinical studies. *Pain Physician*. 2014;17(2):E149-73.
27. Somma F, Gatta G, Negro A, et al. Intradiscal ozone therapy: fluoroscopic guidance reduces operative time in comparison with CT guidance in patients with lumbar disc herniation. *Radiol Med*. 2022;127(5):526-533.
28. Ren L, Guo H, Zhang T, Han Z, Zhang L, Zeng Y. Efficacy evaluation of percutaneous laser disc decompression in the treatment of lumbar disc herniation. *Photomed Laser Surg*. 2013;31(4):174-178.

Downloaded from https://academic.oup.com/painmedicine/article/26/11/741/8149198 by Georgia Institute of Technology user on 14 March 2026

29. Singh V, Manchikanti L, Calodney AK, et al. Percutaneous lumbar laser disc decompression: an update of current evidence. *Pain Physician*. 2013;16(2 Suppl):SE229-60.
30. Carlisle E, Luna M, Tsou PM, Wang JC. Percent spinal canal compromise on MRI utilized for predicting the need for surgical treatment in single-level lumbar intervertebral disc herniation. *Spine J*. 2005;5(6):608-614.
31. Lehnert T, Naguib NN, Wutzler S, et al. Analysis of disk volume before and after CT-guided intradiscal and periganglionic ozone-oxygen injection for the treatment of lumbar disk herniation. *J Vasc Interv Radiol*. 2012;23(11):1430-1436.
32. Geere JH, Swamy GN, Hunter PR, et al. Incidence and risk factors for five-year recurrent disc herniation after primary single-level lumbar discectomy. *Bone Joint J*. 2023;105-B(3):315-322.
33. Pneumaticos SG, Hipp JA, Esses SI. Sensitivity and specificity of dural sac and herniated disc dimensions in patients with low back-related leg pain. *J Magn Reson Imaging*. 2000;12(3):439-443.
34. Desai A, Ball PA, Bekelis K, et al. Outcomes after incidental durotomy during first-time lumbar discectomy. *J Neurosurg Spine*. 2011;14(5):647-653.
35. Galarza M, Gazzeri R, Alfaro R, de la Rosa P, Arraez C, Piqueras C. Evaluation and management of small dural tears in primary lumbar spinal decompression and discectomy surgery. *J Clin Neurosci*. 2018;50:177-182.
36. Koebbe CJ, Maroon JC, Abla A, El-Kadi H, Bost J. Lumbar microdiscectomy: a historical perspective and current technical considerations. *Neurosurg Focus*. 2002;13(2):E3.
37. Shriver MF, Xie JJ, Tye EY, et al. Lumbar microdiscectomy complication rates: a systematic review and meta-analysis. *Neurosurg Focus*. 2015;39(4):E6.
38. Zhong M, Liu JT, Jiang H, et al. Incidence of spontaneous resorption of lumbar disc herniation: a meta-analysis. *Pain Physician*. 2017;20(1):E45-E52.
39. Zou T, Liu XY, Wang PC, et al. Incidence of spontaneous resorption of lumbar disc herniation: a meta-analysis. *Clin Spine Surg*. 2024;37(6):256-269.
40. Ahn SH, Ahn MW, Byun WM. Effect of the transligamentous extension of lumbar disc herniations on their regression and the clinical outcome of sciatica. *Spine (Phila Pa 1976)*. 2000;25(4):475-480.
41. Saal JA, Saal JS, Herzog RJ. The natural history of lumbar intervertebral disc extrusions treated nonoperatively. *Spine (Phila Pa 1976)*. 1990;15(7):683-686.
42. Lin JH, Chiang YH, Chen CC. Lumbar radiculopathy and its neurobiological basis. *WJA*. 2014;3(2):162-173.
43. Lipetz JS. Pathophysiology of inflammatory, degenerative, and compressive radiculopathies. *Phys Med Rehabil Clin N Am*. 2002;13(3):439-449.

Downloaded from https://academic.oup.com/painmedicine/article/26/11/741/8149198 by Georgia Institute of Technology user on 14 March 2026

© The Author(s) 2025. Published by Oxford University Press on behalf of the American Academy of Pain Medicine. All rights reserved.
For commercial re-use, please contact reprints@oup.com for reprints and translation rights for reprints. All other permissions can be obtained through our RightsLink service via the Permissions link on the article page on our site—for further information please contact journals.permissions@oup.com.
Pain Medicine, 2025, 26, 741–748
https://doi.org/10.1093/pm/pnaf070
Original Research Article